

## REVIEW ARTICLE

## MEDICAL PROGRESS

## Commotio Cordis

Barry J. Maron, M.D., and N.A. Mark Estes III, M.D.

**V**ENTRICULAR FIBRILLATION AND SUDDEN DEATH TRIGGERED BY A BLUNT, nonpenetrating, and often innocent-appearing unintentional blow to the chest without damage to the ribs, sternum, or heart (and in the absence of underlying cardiovascular disease) constitute an event known as commotio cordis, which translates from the Latin as agitation of the heart. This term was first used in the 19th century,<sup>1-6</sup> although the occurrence of commotio cordis was described earlier, in accounts of the ancient Chinese martial art of Dim Mak (or touch of death), in which blows to the left of the sternum caused sudden death in opponents.<sup>7</sup> An absence of structural cardiac injury distinguishes commotio cordis from cardiac contusion, in which high-impact blows result in traumatic damage to myocardial tissue and the overlying thorax.

Beginning in the mid-1700s, sporadic accounts of commotio cordis appeared in the medical literature, mostly in the context of workplace accidents,<sup>8-10</sup> and through the mid-1990s, the disorder was noted only occasionally in case reports, going largely unrecognized, except by the forensic pathology community and the Consumer Product Safety Commission.<sup>6,11-14</sup> Since then, however,<sup>1</sup> both the general public and the medical community have become increasingly aware of commotio cordis as an important cause of sudden cardiac death. It occurs primarily in children, adolescents, and young adults, most often during participation in certain recreational or competitive sports, with rare occurrences during normal, routine daily activities.<sup>1,2,6,15-19</sup>

Continued interest in commotio cordis and its tragic consequences is evident in epidemiologic studies<sup>1,2,19</sup> and a number of experimental laboratory investigations.<sup>20-35</sup> This review focuses on the available information regarding the clinical profile, proposed mechanisms, and prevention and treatment of commotio cordis.

## INCIDENCE

The precise incidence of commotio cordis is unknown because of the absence of systematic and mandatory reporting, but on the basis of data from the National Commotio Cordis Registry in Minneapolis,<sup>1,2,17</sup> it is among the most frequent cardiovascular causes of sudden death in young athletes, after hypertrophic cardiomyopathy and congenital coronary-artery anomalies.<sup>17,18</sup> Since commotio cordis occurs in a wide variety of circumstances, it has undoubtedly been underreported but it is being recognized with increasing frequency and is probably more common than it is believed to be.

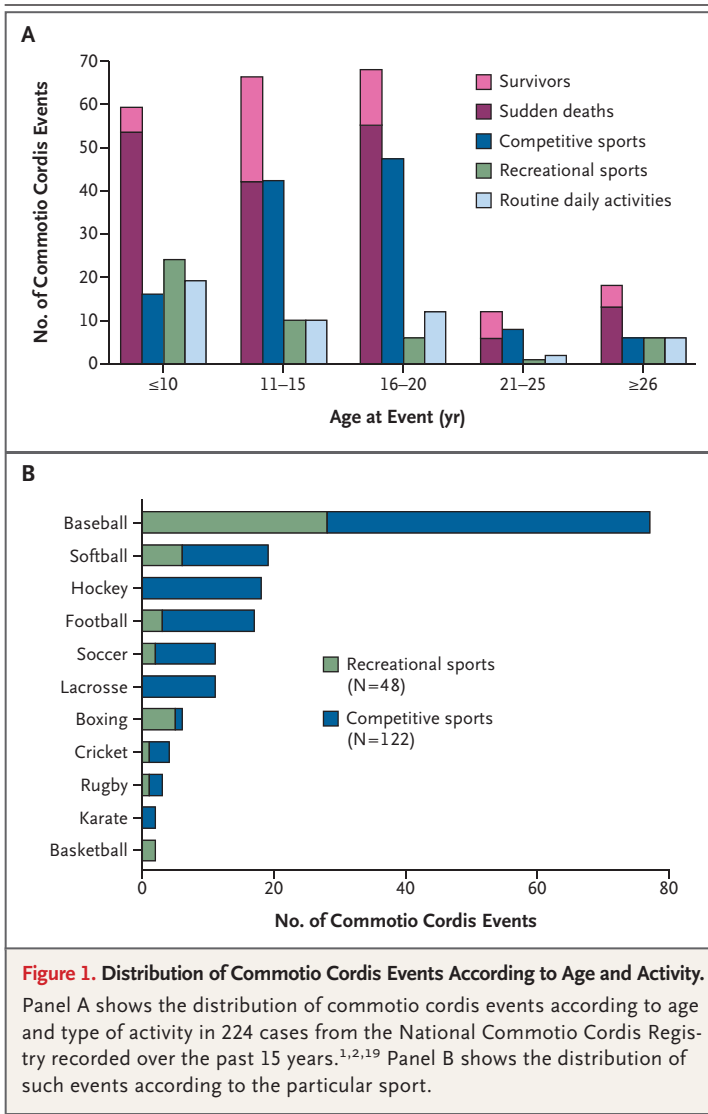
## EPIDEMIOLOGY

In addition to episodic case studies,<sup>8,12-14,36-44</sup> most specific information concerning the clinical profile of commotio cordis comes from the Minneapolis registry,

From the Hypertrophic Cardiomyopathy Center Minneapolis Heart Institute Foundation, Minneapolis (B.J.M.); and the New England Cardiac Arrhythmia Center, Cardiology Division, Tufts University School of Medicine, Boston (N.A.M.E.). Address reprint requests to Dr. Maron at Minneapolis Heart Institute Foundation, 920 E. 28th St., Suite 620, Minneapolis, MN 55407, or at hcm.maron@mhif.org.

N Engl J Med 2010;362:917-27.

Copyright © 2010 Massachusetts Medical Society.



which has documented 224 cases since its creation 15 years ago.<sup>1,2,19</sup> (Fig. 1). Commotio cordis shows a predilection for children and adolescents (mean age, 15±9 years; range, 6 weeks to 50 years). According to the registry, 26% of victims were younger than 10 years of age, and only 9% were 25 years of age or older. The condition has rarely been reported in blacks or in girls or women; most victims are boys or men (95%) and are white (78%). Commotio cordis resulting from blows to the chest from projectiles (predominantly baseballs, softballs, lacrosse balls, or hockey pucks) or blunt bodily contact with other athletes are most common in children younger than 15 years of age.

Although cardiovascular collapse is virtually

instantaneous, 20% of victims remain physically active for a few seconds after the blow (e.g., continuing to walk, run, skate, throw a ball, or even speak), which may reflect individual tolerance for sustained ventricular tachyarrhythmias. For example, a baseball pitcher struck in the chest by a batted ball was able to retrieve the ball at his feet, successfully complete the play (throwing out the base runner), and then prepare for his next pitch before collapsing. In another instance, a batter was struck by a pitch while attempting to bunt and collapsed only after running to first base.

#### COMPETITIVE SPORTS

About 50% of commotio cordis events have been reported in young competitive athletes (mostly those between 11 and 20 years of age) participating in a variety of organized amateur sports — typically baseball, softball, ice hockey, football, or lacrosse — who receive a blow to the chest that is usually (but not always) delivered by a projectile used to play the game. In baseball, for example, commotio cordis is often triggered when players are struck in the chest by balls that have been pitched, batted, or thrown in a variety of scenarios (Table 1, Fig. 2). In hockey, defensive players may intentionally use their chests to block the puck from an opponent's high-velocity shot. High-school and college lacrosse players (including goalies with chest protectors) may be at greater risk for commotio cordis than athletes in other sports that involve similarly solid projectiles (e.g., baseballs).<sup>19</sup> Commotio cordis may also result from physical contact between competitors. Such chest blows are produced by the shoulder, forearm, elbow, leg, foot, or head, as when two outfielders inadvertently collide while tracking a baseball in the air, or, alternatively, when a hockey stick is thrust into an opponent's chest.

#### RECREATIONAL SPORTS

Another 25% of commotio cordis events occur in recreational sports played at home, on the playground, or at picnics or other family gatherings. These innocent-appearing events occur with disproportionate frequency in the youngest known victims (10 years old or younger), with close family members (e.g., parents or siblings) or friends often responsible for the blow. In one example, a child playing catch with a parent misjudged the flight of the ball, which was then deflected off his glove, striking his chest. In recreational sports,

**Table 1. Examples of Circumstances in Which Chest Blows Have Triggered Commotio Cordis.****Sports**

Baseball, softball, cricket

- Batter struck by a pitched ball
- Batter hit by pitched ball while attempting to bunt
- Pitcher hit by a batted or thrown ball
- Base runner hit by a batted or thrown ball while running or sliding
- Player inadvertently in path of thrown or batted ball
- Catcher, umpire, spectator, or bystander hit by a foul ball
- Batter on deck hit by an errant throw
- Catcher struck by a bat
- Fielders or base runners involved in bodily collision
- Fielder hit when flight of ball was misjudged and ball deflected off glove
- Player fell on softball after catching it
- Player hit by bowled cricket ball

Football

- Player hit in bodily collision with opponent's helmet, forearm, shoulder, or knee, usually during blocking or tackling or after pass reception
- Player struck by ball while blocking punt

Soccer

- Player collided with goalpost
- Goalie struck by shot on goal
- Player kicked in chest by opponent

Hockey

- Goalie or other defensive player struck by shot on goal
- Player hit in bodily collision involving checking
- Player struck by slap shot — hockey puck traveling at high speed
- Player struck by hockey stick

Lacrosse

- Goalie hit by high-velocity shot on goal
- Player hit by ball passed from teammate

**Fights and scuffles, with blow from hand or elbow**

- Psychiatric aide struck by patient
- Teacher struck while restraining student during fight
- Youth struck during play — shadowboxing or roughhousing
- Youth struck by boxing glove during sparring
- Child struck by parent or babysitter (with disciplinary intent)
- Young adult struck during slam dancing
- Student involved in fist fight at fraternity party
- Youth hit by snowball
- Adult struck in prison gang initiation ritual
- Infant struck with open hand while having diaper changed

**Other circumstances**

- Child kicked by horse
- Youth hit with recoil of gun butt while deer hunting
- Child hit with rebound of playground swing
- Adult thrown against steering wheel during automobile accident
- Youth hit by tennis ball filled with coins
- Young adult kicked during cheerleading routine
- Adult received chest blow by falling into body of water
- Child received blow from head of 23-kg (50-lb) pet dog
- Child received blow from falling on playground apparatus
- Child hit by tossed hollow plastic bat
- Child hit by plastic sledding saucer
- Youth received blow intended to terminate hiccups
- Child hit handlebars while falling off bicycle

the speed of the projectiles causing chest blows ranges widely, from the low-velocity balls thrown during informal games of catch to high-velocity lacrosse or cricket balls.

#### OTHER ACTIVITIES

Comotio cordis is unrelated to sports activities in about 25% of victims (most often the youngest) (Fig. 1). These incidents occur in a wide variety of circumstances, such as being kicked in the chest by a horse or struck by a playground swing as it rebounds. On occasion, such accidents are brought to court. Charges of murder or manslaughter have led to criminal prosecution and incarceration.<sup>45-49</sup>

#### OUTCOME

Comotio cordis is usually, although not invariably, fatal.<sup>1,2,19,50,51</sup> In only about 25% of the cases reported in the Minneapolis registry has cardiopulmonary resuscitation or defibrillation resulted in survival — a low percentage, considering that commotio cordis is defined by the absence of structural heart disease. The outcome is related largely to the circumstances in which commotio cordis occurs. Deaths have often been associated with the failure of bystanders to appreciate the life-threatening nature of the collapse and to initiate appropriately aggressive and timely measures of resuscitation.<sup>2,17</sup>

Registry data show that survival rates have increased over time, rising to 35% over the past decade, as compared with 15% for the preceding 10 years ( $P=0.01$ ); most recently — between 2006 and 2009 — the number of successful resuscitations exceeded the number of deaths by 20%. This improvement is probably the result of increased public awareness, the increased availability of automatic external defibrillators (AEDs), and earlier activation of the chain of survival (call to 911 and initiation of cardiopulmonary resuscitation, defibrillation, and advanced life-support measures). Arrhythmias recorded at the time of collapse or in the emergency room are often caused by ventricular fibrillation,<sup>2</sup> suggesting that restoration of sinus rhythm and survival are possible, given prompt defibrillation.

Some commotio cordis events may abort spontaneously, when the blow causes nonsustained arrhythmias, although this is difficult to confirm. Such cases have been recorded in the reg-

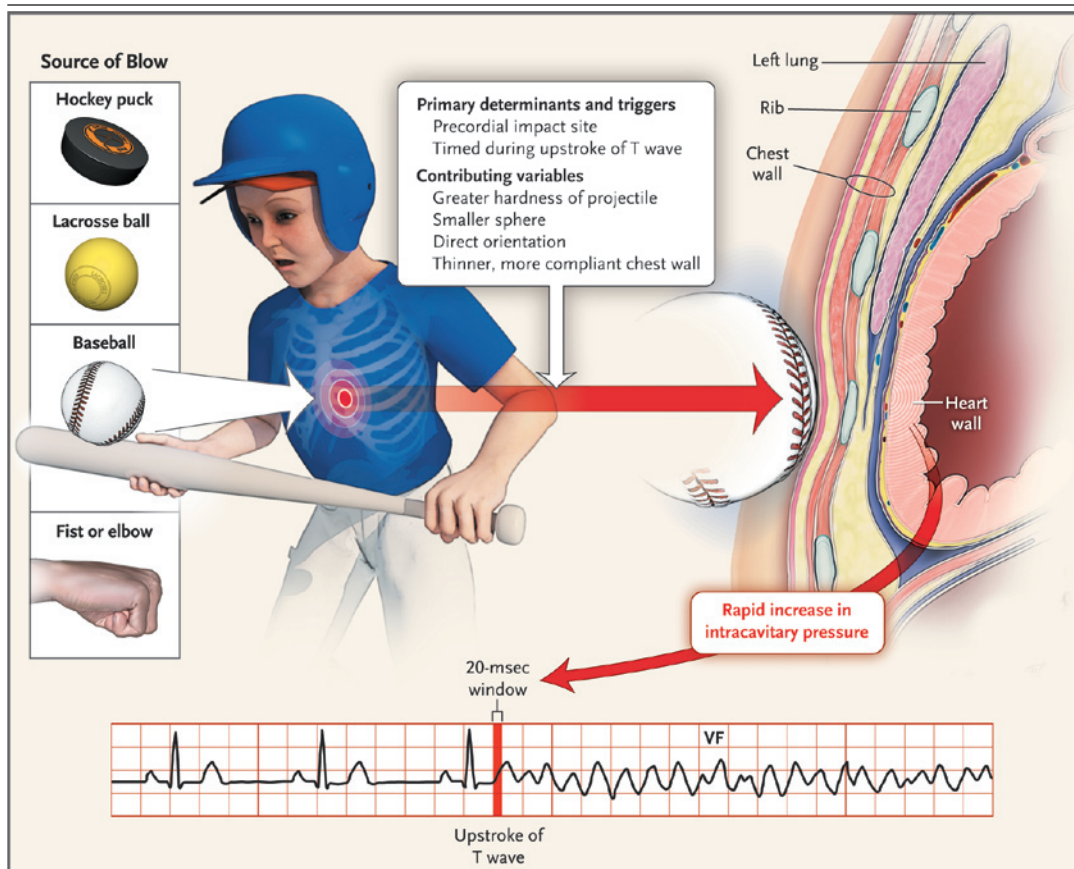
istry, including the case of a professional hockey player who collapsed immediately after being struck in the chest by a puck traveling at high velocity. The player's slow pulse suggested transient complete heart block (or another bradyarrhythmia), as has been reported in laboratory settings, in which a blow to the chest is timed to occur during the QRS complex<sup>20</sup>; the player regained consciousness spontaneously, within a few minutes after his collapse, and recovered.<sup>52</sup>

#### MECHANISMS

Comotio cordis is a primary arrhythmic event that occurs when the mechanical energy generated by a blow is confined to a small area of the precordium and profoundly alters the electrical stability of the myocardium, resulting in ventricular fibrillation. A variety of biologic and biomechanical experimental models of commotio cordis have been developed to elucidate the mechanisms by which a rapid mechanical stimulus to the chest triggers ventricular fibrillation.<sup>3,4,8,20,25-29,34,35,53-55</sup> Early efforts, dating back to the late 19th century, to replicate commotio cordis in animals were relatively crude, making use of hammers and other blunt instruments that often resulted in death from direct trauma.<sup>3,4,8,9</sup> These early investigations yielded several theoretical explanations for the mechanics of the event, including excessive autonomic (vagal) reflex<sup>6,8,9</sup> and coronary arterial vasospasm,<sup>3,4,6,8</sup> that have since been abandoned. During testing in later models, baseballs were propelled at speeds of up to 153 km (95 mi) per hour, causing severe injuries to the thorax and heart (cardiac contusion) but not commotio cordis.<sup>53</sup>

#### DETERMINANTS AND TRIGGERS

More recent experimental laboratory studies conducted under controlled conditions in pigs, dogs, and rabbits<sup>20-27,29-35,53</sup> have provided insights into the underlying mechanisms of commotio cordis that are consistent with its clinical profile and have dispelled the notion that sudden death after a blow to the chest is a mysterious phenomenon.<sup>1,2</sup> One model, in which projectile-induced blows were delivered at a wide range of velocities to anesthetized young pigs in synchronization with the cardiac cycle, revealed two critically important mechanical determinants of ventricular fibrillation and lethality (Fig. 2).<sup>20,33</sup>



**Figure 2. Pathophysiology of Commotio Cordis.**

In recreational and competitive sports, chest blows may involve balls or pucks or may be inflicted through bodily contact. The location of the blow on the chest and its timing relative to the cardiac cycle are the primary determinants of commotio cordis. Other factors that may contribute to the risk of an event include the density, size, and orientation of the projectile and the shape of the thorax; younger people are the most vulnerable because of their thinner, less developed rib cage and musculature.

The first of these determinants involves the location of the blow, which must be directly over the heart (particularly at or near the center of the cardiac silhouette).<sup>20,33</sup> This finding is consistent with clinical observations that precordial bruises representing the imprint of a blow are frequently evident in victims.<sup>1,2</sup> There is no evidence in humans or in experimental models that blows sustained outside the precordium (e.g., the back, the flank, or the right side of the chest) cause sudden death.<sup>27,33</sup>

The second determinant concerns the timing of the blow, which must occur within a narrow window of 10 to 20 msec on the upstroke of the T wave, just before its peak (accounting for only 1% of the cardiac cycle) — that is, the blow must occur during an electrically vulnerable period,

when inhomogeneous dispersion of repolarization is greatest, creating a susceptible myocardial substrate for provoked ventricular fibrillation (Fig. 2).<sup>20</sup> In pigs, when blows occurred outside this brief window of time, ventricular fibrillation was not the consequence; instead, what followed was transient complete heart block, left bundle-branch block, or ST-segment elevation.<sup>20</sup> These effects have also been reported in some human survivors (with the presumed timing of the blow coinciding with the QRS complex during ventricular depolarization).<sup>12,50</sup>

The energy of the impact associated with commotio cordis is not uniform, characteristically encompassing a wide range of velocities as well as projectile sizes, shapes, and weights. Projectiles include hockey pucks and lacrosse balls



propelled at speeds of up to 145 km (90 mi) per hour,<sup>1,2</sup> as well as seemingly innocuous objects, such as plastic toy bats and sledding saucers, that can become lethal when striking small children, even at slow speeds. Under experimental conditions, the likelihood that ventricular fibrillation will be triggered by a projectile the size of a baseball increases progressively up to an impact velocity of 64 km (40 mi) per hour, a speed typically delivered by 11- and 12-year-old pitchers.<sup>24</sup> At higher velocities (exceeding 80 km [50 mi] per hour), there is an increased risk of structural damage to the chest and heart, including myocardial bruising and rupture that are characteristic of cardiac contusion (rather than commotio cordis).<sup>24,53</sup>

Other factors that may increase the risk of ventricular fibrillation and commotio cordis include the hardness of the object and its size and shape, with hard, small, sphere-shaped projectiles most likely to do harm.<sup>20,23,56</sup> The predisposition to commotio cordis in young people may largely be related to physical characteristics of the thorax in the young<sup>33,56</sup>; the relatively thin, underdeveloped, compliant chest cage (and immature intercostal musculature) is less capable of blunting the arrhythmogenic consequences of precordial blows.<sup>1,2</sup> In addition, since children probably incur chest blows more frequently than adults in a variety of circumstances, they may generally be at greater risk for commotio cordis.

Adults probably gain a measure of protection from their mature and fully developed chest cage, which may explain in part the apparently low rate of commotio cordis events in sports such as kickboxing and boxing (accounting for less than 5% of registry cases). In boxing, it is also possible that the glove itself, which increases the area of impact, helps to buffer the force of the blow.<sup>2</sup>

The question of whether susceptibility to commotio cordis varies because of individual variations in the length of the QT interval has been considered but remains unanswered. There is no evidence that survivors of commotio cordis are at increased risk for subsequent arrhythmic events, nor is there evidence that athletes who have had a commotio cordis event should be disqualified from competition solely for that reason. Similarly, prophylactic implantable defibrillators are not indicated for persons who have survived commotio cordis in the absence of cardiac disease.

#### CELLULAR MECHANISMS

The cellular (and subcellular) mechanisms responsible for commotio cordis appear to be multifactorial and complex, and they remain incompletely defined. Information obtained from experiments with Langendorff preparations of perfused rabbit heart<sup>27</sup> and from animal models<sup>21,24,30-32</sup> has led to hypotheses concerning specific mechanistic pathways. It is believed that the mechanical force generated by precordial blows during repolarization causes left ventricular intracavitary pressure to rise instantaneously to 250 to 450 mm Hg; this rise in pressure is directly correlated with an increased probability of ventricular fibrillation.<sup>21,24,27,33</sup> It has been hypothesized that this elevation in pressure causes cell membranes to stretch, activating ion channels and increasing transmembrane current flow by means of mechanical–electric coupling.<sup>21,26,27,29,30,35</sup> The resultant amplified dispersion of repolarization creates an inhomogeneous and electrically vulnerable substrate that is susceptible to ventricular fibrillation. The candidate ion channels include the ATP-sensitive potassium channel,<sup>26</sup> which contributes to the initiation of ventricular fibrillation in commotio cordis<sup>21</sup> and in myocardial infarction and ischemia.<sup>57-62</sup> It is possible that the mechanism by which ventricular fibrillation occurs in commotio cordis, with ventricular depolarization induced by a blow to the chest, has something in common with the pathophysiological mechanisms that give rise to primary arrhythmogenic conditions, such as ion channelopathies.<sup>63-68</sup>

---

#### PREVENTIVE STRATEGIES AND FUTURE CONSIDERATIONS

---

##### PRIMARY PREVENTION

The risk of commotio cordis is associated with lifestyle and therefore can be modified. One means of prevention is public education — people should be made aware of the importance of avoiding precordial blows.<sup>56</sup> It is particularly important to increase awareness that even an unintentional, modest-seeming blow to the chest delivered without malice (e.g., in playful boxing) can trigger life-threatening ventricular tachyarrhythmias.<sup>2</sup> Even so, since there are so many circumstances in which commotio cordis can occur (Table 1), elimination of these events is an unrealistic goal.

Organized sports present the greatest oppor-

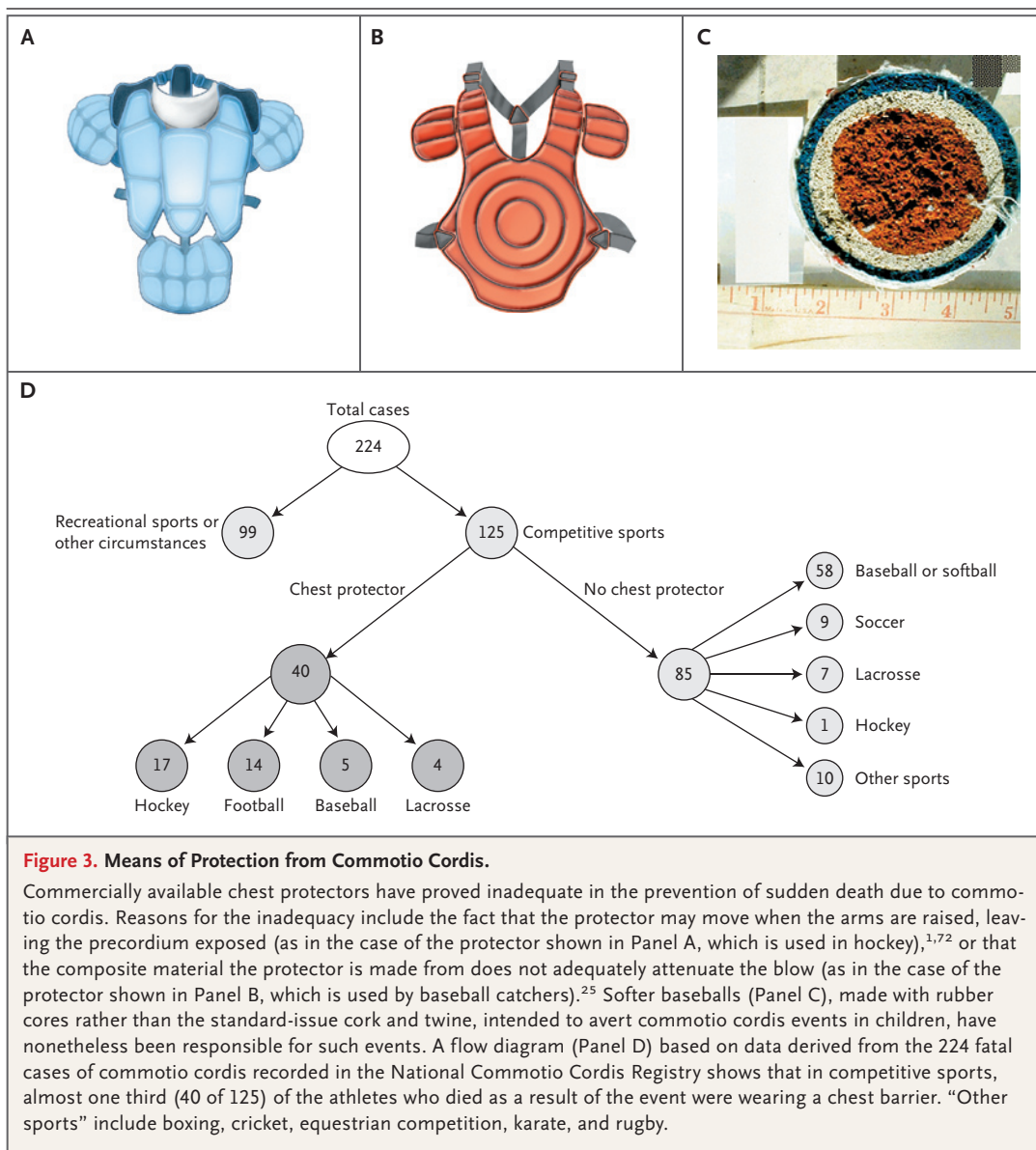
tunity to prevent commotio cordis. For example, the risk would probably be reduced by means of improved coaching techniques, such as teaching inexperienced young batters in baseball and softball how to turn away from the ball to avoid errant pitches.<sup>56,69</sup> Defensive players in lacrosse and hockey can be coached to avoid using their chest to block the ball or puck when protecting their goal. Coaching clinics sponsored by the National Collegiate Athletic Association now strongly discourage any tactic that places lacrosse players (who are not goalies) directly in the path of shots on goal.

Improved design of commercial sports equipment would also probably help to prevent commotio cordis. One example is the safety baseball, a softer ball intended for players younger than 13 years of age; the safety baseball is made entirely of rubber, without the dense, hard core of cork and twine found in standard baseballs. A direct relation between the hardness of the ball and the likelihood of ventricular fibrillation has been demonstrated in the laboratory, and lethal arrhythmias occur less frequently when the balls used have been manufactured for reduced hardness.<sup>20,23,56</sup> However, softer balls will not be accepted if they change the nature of the game, and their absolute effectiveness in reducing the risk of commotio cordis has not been documented in the field. In fact, so-called safety baseballs have been responsible for several fatal events.<sup>2</sup> The observation that the air-filled balls used in soccer, tennis, and basketball are rarely implicated in commotio cordis (accounting for only 4% of projectile-related deaths, according to the Minneapolis registry) is consistent with the principle that solid projectiles are more likely to precipitate ventricular fibrillation; air-filled balls are presumed to be safer because of their propensity to collapse, or give, on contact and to absorb some of the energy of the impact.

Chest protectors and vests have been a focus for primary prevention of commotio cordis in certain sports.<sup>34,54,56,70,71</sup> However, registry data indicate that the most commonly used, commercially available protectors, which were originally designed to reduce the likelihood of trauma from blunt bodily injury — but not to provide protection against commotio cordis — do not offer absolute protection from arrhythmia after a blow to the chest.<sup>1,2,19,70</sup> Indeed, currently available chest protectors may create a false sense of secu-

rity, given that almost 20% of the victims of commotio cordis in competitive football, baseball, lacrosse, and hockey were wearing equipment marketed as providing protection against traumatic chest injury (Fig. 3).<sup>1,2,9,70,72</sup> In several fatal cases of commotio cordis in lacrosse goalies, the ball struck the chest protector directly.<sup>19</sup> Such cases suggest that the material the protectors were made from was inadequate. In other cases of commotio cordis, a flawed design of the chest barrier allowed the projectile direct access to the precordium. For example, in hockey, when a player's arms are fully raised, the protector can migrate upward, exposing the chest wall to a direct blow.<sup>1,70,72</sup> Confirmatory evidence from animal models indicates that the commercially produced chest protectors now promoted for use in baseball and lacrosse are ineffective in consistently preventing ventricular fibrillation — that is, wearing such protectors does not reduce the risk of sudden death.<sup>25,34</sup>

Development of a chest barrier that is adequately designed to prevent commotio cordis during sports competition may prove difficult. To be effective, a chest protector would have to absorb and dissipate the energy generated by the precordial impact.<sup>56</sup> In laboratory studies, a mechanical model that could diffuse the force of chest blows over an increased surface area was most effective in preventing commotio cordis.<sup>54</sup> Furthermore, both clinical observations<sup>1,2,19</sup> and laboratory data<sup>25,34,70</sup> suggest that closed-cell foam, which is the primary constituent of most commercially available chest protectors, is easily penetrated by projectiles and does not provide adequate protection against commotio cordis. It is likely that chest protectors would be more effective if they were made from harder, more rigid, and more resistant materials and from foams capable of absorbing and dispersing greater amounts of energy. In practical design terms, such a chest protector should be adaptable for use by athletes playing any position in any sport in which there is a risk of commotio cordis; currently, the use of such protectors is largely limited to goalies in lacrosse and hockey and to catchers in baseball, positions that have been associated with 20% of all commotio cordis events.<sup>70</sup> An ideal chest-wall protector would also have to be affordable, durable, and compatible with the full range of physical activity and comfort required by athletes in a given sport and



would have to meet prespecified performance standards.<sup>54</sup>

#### SECONDARY PREVENTION

AEDs have substantial life-saving capability, and it is appropriate to disseminate them widely at youth sporting events and recreational settings where commotio cordis may occur.<sup>73</sup> A public health strategy that incorporates a plan for making AEDs widely available is likely to result in the survival of more young people in the event of commotio cordis, as indicated by current registry data and several cases in which an AED was effective

in terminating life-threatening ventricular tachyarrhythmias and restoring sinus rhythm.<sup>2,69,74,75</sup> Indeed, AEDs have also effectively terminated ventricular fibrillation in animal models of commotio cordis.<sup>22</sup> However, even under optimal conditions, an AED can fail to restore the heart to normal rhythm after commotio cordis, as was the case with a college lacrosse player who was not a goalie but was struck in the chest by a ball and died, despite particularly prompt efforts at resuscitation and defibrillation.<sup>76</sup> Both clinical studies<sup>77-81</sup> and experimental studies<sup>82</sup> suggest that precordial thumps are unreliable in



terminating ventricular fibrillation caused by chest blows.

---

SUMMARY

---

In the past decade, the general public and the medical community have become more aware of commotio cordis as an important cause of sudden death. Commotio cordis occurs in otherwise healthy and active young people, typically during recreational and competitive sports but in some cases even during normal daily activities. A variety of experimental models indicate that if delivered at a particular moment in the cardiac cycle, even innocent-appearing precordial blows can trigger ventricular fibrillation and result in fatal com-

motio cordis events. Further efforts are needed to prevent these largely avoidable deaths by providing more education, better-designed athletic equipment (e.g., effective chest-wall protectors), and wider access to AEDs at organized athletic events. These strategies should result in a safer sports environment for our youth.

Supported in part by grants from the Hearst Foundations, the Louis J. Acompora Memorial Foundation, and the National Operating Committee on Standards for Athletic Equipment.

Dr. Maron reports receiving consulting fees from GeneDx (a subsidiary of Bio-Reference Laboratories) and lecture fees and grant support from Medtronic. Dr. Estes reports that his institution has received fellowship funding from St. Jude Medical, Boston Scientific, and Medtronic and that he has received lecture fees and travel support from Boston Scientific.

We thank David Mottet for his assistance with an earlier version of Figure 2.

---

REFERENCES

- Maron BJ, Poliac L, Kaplan JA, Mueller FO. Blunt impact to the chest leading to sudden death from cardiac arrest during sports activities. *N Engl J Med* 1995;333:337-42.
- Maron BJ, Gohman TE, Kyle SB, Estes NAM III, Link MS. Clinical profile and spectrum of commotio cordis. *JAMA* 2002;287:1142-6.
- Schlomka G, Hinrichs A. Experimentelle Untersuchungen über den Einfluss stumpfer Brustkorbverletzungen auf das Elektrokardiogramm. *Z Ges Exp Med* 1932;31:43-61.
- Schlomka G. Commotio cordis und ihre Folgen: Die einwirkung stumpfer Brustwandtraumen auf das Herz. *Ergeb Inn Med Kinderheilkd* 1934;47:1-91.
- Casper JL. *Praktisches Handbuch der Gerichtlichen Medizin*. Berlin: Verlag von August Hirschwald, 1857.
- Nesbitt AD, Cooper PJ, Kohl P. Rediscovering commotio cordis. *Lancet* 2001;357:1195-7.
- Kelly M. *Death touch: the science behind the legend of Dim-Mak*. Boulder, CO: Paladin Press, 2001.
- Frazer M, Mirchandani H. Commotio cordis, revisited. *Am J Forensic Med Pathol* 1984;5:249-51.
- Meola F. La commozione toracica. *Gior Internaz Sci Med* 1879;1:923-37.
- Maron BJ, Doerer JJ, Haas TS, Estes NAM III, Link MS. A historical observation on commotio cordis. *Heart Rhythm* 2006;3:605-7.
- Rutherford GW, Kennedy J, McGhee L. *Baseball and softball related injuries to children 5-14 years of age*. Washington, DC: Consumer Product Safety Commission, 1984.
- Abrunzo TJ. Commotio cordis: the single, most common cause of traumatic death in youth baseball. *Am J Dis Child* 1991;145:1279-82.
- Dickman GI, Hassan A, Luckstead EF. Ventricular fibrillation following baseball injury. *Physician Sports Med* 1978;6:85-6.
- Green ED, Simson LR Jr, Kellerman HH, Horowitz RN, Sturmer WQ. Cardiac concussion following softball blow to the chest. *Ann Emerg Med* 1980;9:155-7.
- Zangwill SD, Strasburger JF. Commotio cordis. *Pediatr Clin North Am* 2004;51:1347-54.
- Boden BP, Tacchetti R, Mueller FO. Catastrophic injuries in high school and college baseball players. *Am J Sports Med* 2004;32:1189-96.
- Maron BJ. Sudden death in young athletes. *N Engl J Med* 2003;349:1064-75.
- Maron BJ, Doerer JJ, Haas TS, Tierney DM, Mueller FO. Sudden deaths in young competitive athletes: analysis of 1866 deaths in the United States, 1980-2006. *Circulation* 2009;119:1085-92.
- Maron BJ, Doerer JJ, Haas TS, Estes NAM III, Hodges JS, Link MS. Commotio cordis and the epidemiology of sudden death in competitive lacrosse. *Pediatrics* 2009;124:966-71.
- Link MS, Wang PJ, Pandian NG, et al. An experimental model of sudden death due to low-energy chest-wall impact (commotio cordis). *N Engl J Med* 1998;338:1805-11.
- Link MS, Wang PJ, VanderBrink BA, et al. Selective activation of the  $K^+_{ATP}$  channel is a mechanism by which sudden death is produced by low energy chest wall impact (commotio cordis). *Circulation* 1999;100:413-8.
- Link MS, Maron BJ, Stickney RE, et al. Automated external defibrillator arrhythmia detection in a model of cardiac arrest due to commotio cordis. *J Cardiovasc Electrophysiol* 2003;14:83-7.
- Link MS, Maron BJ, Wang PJ, Pandian NG, VanderBrink BA, Estes NAM III. Reduced risk of sudden death from chest wall blows (commotio cordis) with safety baseballs. *Pediatrics* 2002;109:873-7.
- Link MS, Maron BJ, Wang PJ, VanderBrink BA, Zhu W, Estes NAM III. Upper and lower limits of vulnerability to sudden arrhythmic death with chest wall impact (commotio cordis). *J Am Coll Cardiol* 2003;41:99-104.
- Weinstock J, Maron BJ, Song C, Mane PP, Estes NAM III, Link MS. Failure of commercially available chest wall protectors to prevent sudden cardiac death induced by chest wall blows in an experimental model of commotio cordis. *Pediatrics* 2006;117(4):e656-e662.
- Kohl P, Nesbitt AD, Cooper PJ, Lei M. Sudden cardiac death by commotio cordis: role of mechano-electric feedback. *Cardiovasc Res* 2001;50:280-9.
- Bode F, Franz MR, Wilke I, Bonnemeier H, Schunkert H, Wiegand UK. Ventricular fibrillation induced by stretch pulse: implications for sudden death due to commotio cordis. *J Cardiovasc Electrophysiol* 2006;17:1011-7.
- Cooper GJ, Pearce BP, Stainer MC, Maynard RL. The biomechanical response of the thorax to nonpenetrating impact with particular reference to cardiac injuries. *J Trauma* 1982;22:994-1008.
- Liedtke AJ, Allen RP, Nellis SH. Effects of blunt cardiac trauma on coronary vasomotion, perfusion, myocardial mechanics, and metabolism. *J Trauma* 1980;20:777-85.
- Madias C, Maron BJ, Supron S, Estes NAM III, Link MS. Cell membrane stretch and chest blow-induced ventricular fibrillation (commotio cordis). *J Cardiovasc Electrophysiol* 2008;19:1304-9.
- Garan AR, Maron BJ, Wang PJ, Estes NAM III, Link MS. Role of streptomycin-sensitive stretch activated channel in chest wall impact induced sudden death (com-

- motio cordis). *J Cardiovasc Electrophysiol* 2005;16:433-8.
32. Stout CW, Maron BJ, Vanderbrink BA, Estes NAM III, Link MS. Importance of the autonomic nervous system in an experimental model of commotio cordis. *Med Sci Monit* 2007;13:BR11-BR15.
33. Link MS, Maron BJ, VanderBrink BA, et al. Impact directly over the cardiac silhouette is necessary to produce ventricular fibrillation in an experimental model of commotio cordis. *J Am Coll Cardiol* 2001;37:649-54.
34. Viano DC, Bir CA, Cheney AK, Janda DH. Prevention of commotio cordis in baseball: an evaluation of chest protectors. *J Trauma* 2000;49:1023-8.
35. Liedtke AJ, Gault JH, Demuth WE. Electrocardiographic and hemodynamic changes following nonpenetrating chest trauma in the experimental animal. *Am J Physiol* 1974;226:377-82.
36. Hamilton SJ, Sunter JP, Cooper PN. Commotio cordis — a report of three cases. *Int J Legal Med* 2005;119:88-90.
37. Tibballs J, Thiruchelvam T. A case of commotio cordis in a young child caused by a fall. *Resuscitation* 2008;77:139-41.
38. Lucena JS, Rico A, Salguero M, Blanco M, Vázquez R. Commotio cordis as a result of a fight: report of a case considered to be imprudent homicide. *Forensic Sci Int* 2008;177(1):e1-e4.
39. Crown LA, Hawkins W. Commotio cordis: clinical implications of blunt cardiac trauma. *Am Fam Physician* 1997;55:2467-70.
40. Deady B, Innes G. Sudden death of a young hockey player: case report of commotio cordis. *J Emerg Med* 1999;17:459-62.
41. Wang J-N, Tsai Y-C, Chen S-L, Chen Y, Lin C-S, Wu J-M. Dangerous impact — commotio cordis. *Cardiology* 2000;93:124-6.
42. Thakore S, Johnston M, Rogena E, Peng Z, Sadler D. Non-penetrating chest blows and sudden death in the young. *J Accid Emerg Med* 2000;17:421-2.
43. Edlich RF Jr, Mayer NE, Fariss BL, et al. Commotio cordis in a lacrosse goalie. *J Emerg Med* 1987;5:181-4.
44. Pearce PZ. Commotio cordis: sudden death in a young hockey player. *Curr Sports Med Rep* 2005;4:157-9.
45. Maron BJ, Mitten MJ, Greene Burnett C. Criminal consequences of commotio cordis. *Am J Cardiol* 2002;89:210-3.
46. Denton JS, Kalelkar MB. Homicidal commotio cordis in two children. *J Forensic Sci* 2000;45:734-5.
47. Boglioli LR, Taff ML, Harleman G. Child homicide caused by commotio cordis. *Pediatr Cardiol* 1998;19:436-8.
48. Baker AM, Craig BR, Lonergan GJ. Homicidal commotio cordis: the final blow in a battered infant. *Child Abuse Negl* 2003;27:125-30.
49. Froede RC, Lindsey D, Steinbronn K. Sudden unexpected death from cardiac concussion (commotio cordis) with unusual legal complications. *J Forensic Sci* 1979;24:752-6.
50. Link MS, Ginsburg SH, Wang PJ, Kirchlöffler JB, Estes NAM III, Parris YM. Commotio cordis: cardiovascular manifestation of a rare survivor. *Chest* 1998;114:326-8.
51. Maron BJ, Strasburger JF, Kugler JD, Bell BM, Brodkey FD, Poliac LC. Survival following blunt chest impact-induced cardiac arrest during sports activities in young athletes. *Am J Cardiol* 1997;79:840-1.
52. Maron BJ, Pelliccia A. The heart of trained athletes: cardiac remodeling and the risks of sports including sudden death. *Circulation* 2006;114:1633-44.
53. Viano DC, Andrzejak DV, Polley TZ, King AI. Mechanism of fatal chest injury by baseball impact: development of an experimental model. *Clin J Sport Med* 1992;2:166-71.
54. Drewniak EI, Spenciner DB, Crisco JJ. Mechanical properties of chest protectors and the likelihood of ventricular fibrillation due to commotio cordis. *J Appl Biomech* 2007;23:282-8.
55. Bir CA, Viano DC. Biomechanical predictor of commotio cordis in high-speed chest impact. *J Trauma* 1999;47:468-73.
56. Link MS, Bir C, Dau N, Madias C, Estes NAM III, Maron BJ. Protecting our children from the consequences of chest blows on the playing field: a time for science over marketing. *Pediatrics* 2008;122:437-9.
57. Bekheit S-S, Restivo M, Boutjdir M, et al. Effects of glyburide on ischemia-induced changes in extracellular potassium and local myocardial activation: a potential new approach to the management of ischemia-induced malignant ventricular arrhythmias. *Am Heart J* 1990;119:1025-33.
58. Kubota I, Yamaki M, Shibata T, Ikano E, Hosoya Y, Tomoike H. Role of ATP-sensitive K<sup>+</sup> channel on ECG ST segment elevation during a bout of myocardial ischemia: a study on epicardial mapping in dogs. *Circulation* 1993;88:1845-51.
59. Kondo T, Kubota I, Tachibana H, Yamaki M, Tomoike H. Glibenclamide attenuates peaked T wave in early phase of myocardial ischemia. *Cardiovasc Res* 1996;31:683-7.
60. Kantor PF, Coetzee WA, Carmeliet EE, Dennis SC, Opie LH. Reduction of ischemic K<sup>+</sup> loss and arrhythmias in rat hearts: effect of glibenclamide, a sulfonylurea. *Circ Res* 1990;66:478-85.
61. Van Wagoner DR. Mechanosensitive gating of atrial ATP-sensitive potassium channels. *Circ Res* 1993;72:973-83.
62. Turitto G, Dini P, Prati PL. The R on T phenomenon during transient myocardial ischemia. *Am J Cardiol* 1989;63:1520-2.
63. Haïssaguerre M, Extramiana F, Hocini M, et al. Mapping and ablation of ventricular fibrillation associated with long-QT and Brugada syndromes. *Circulation* 2003;108:925-8.
64. Shimizu W, Antzelevitch C. Cellular basis for the ECG features of the LQT1 form of the long-QT syndrome: effects of beta-adrenergic agonists and antagonists and sodium channel blockers on transmural dispersion of repolarization and torsade de pointes. *Circulation* 1998;98:2314-22.
65. Viswanathan PC, Rudy Y. Cellular arrhythmogenic effects of congenital and acquired long QT syndromes in the heterogeneous myocardium. *Circulation* 2000;101:1192-8.
66. Gussak I, Antzelevitch C, Bjerregaard P, Towbin JA, Chaitman BR. The Brugada syndrome: clinical, electrophysiologic and genetic aspects. *J Am Coll Cardiol* 1999;33:5-15.
67. Yan GX, Antzelevitch C. Cellular basis for the Brugada syndrome and other mechanisms of arrhythmogenesis associated with ST-segment elevation. *Circulation* 1999;100:1660-6.
68. Antzelevitch C, Oliva A. Amplification of spatial dispersion of repolarization underlies sudden cardiac death associated with catecholaminergic polymorphic VT, long QT, short QT and Brugada syndromes. *J Intern Med* 2006;259:48-58.
69. Strasburger JF, Maron BJ. Commotio cordis. *N Engl J Med* 2002;347:1248.
70. Doerer JJ, Haas TS, Estes NAM III, Link MS, Maron BJ. Evaluation of chest barriers for protection against sudden death due to commotio cordis. *Am J Cardiol* 2007;99:857-9.
71. Janda DH, Viano DC, Andrzejak DV, Hensinger RN. An analysis of preventive methods for baseball-induced chest impact injuries. *Clin J Sport Med* 1992;2:172-9.
72. Kaplan JA, Karofsky PS, Volturo GA. Commotio cordis in two amateur ice hockey players despite the use of commercial chest protectors: case reports. *J Trauma* 1993;34:151-3.
73. Myerburg RJ, Estes NAM III, Fontaine JM, Link MS, Zipes DP. Task Force 10: automated external defibrillators. *J Am Coll Cardiol* 2005;45:1369-71.
74. Lee C-C, Chang W-T, Chen S-C, Yen Z-S, Chen W-J. Successful resuscitation after sudden death in a one year old infant who sustained a blunt chest injury from a fall from 10 m. *Resuscitation* 2005;64:241-3.
75. Salib EA, Cyran SE, Cilley RE, Maron BJ, Thomas NJ. Efficacy of bystander cardiopulmonary resuscitation and out-of-hospital automated external defibrillation as life-saving therapy in commotio cordis. *J Pediatr* 2005;147:863-6.
76. Maron BJ, Wentzel DC, Zenovich AG, Estes NAM III, Link MS. Death in a young athlete due to commotio cordis despite prompt external defibrillation. *Heart Rhythm* 2005;2:991-3.

- 77.** Amir O, Schliamser JE, Nemer S, Arie M. Ineffectiveness of precordial thump for cardioversion of malignant ventricular tachyarrhythmias. *Pacing Clin Electrophysiol* 2007;30:153-6.
- 78.** Efimov IR, Fedorov VV. Precordial thump and commotio cordis: the yin and yang of mechanoelectric feedback in the heart. *Heart Rhythm* 2006;3:187-8.
- 79.** Miller JM, Bhakta D. The precordial thump: convertio cordis, commotio cordis, or neither? *Pacing Clin Electrophysiol* 2007;30:151-2.
- 80.** Pellis T, Kette F, Lovisa D, et al. Utility of pre-cordial thump for treatment of out of hospital cardiac arrest: a prospective study. *Resuscitation* 2009;80:17-23.
- 81.** Haman L, Parizek P, Vojacek J. Precordial thump efficacy in termination of induced ventricular arrhythmias. *Resuscitation* 2009;80:14-6.
- 82.** Madias C, Maron BJ, Alsheikh-Ali AA, Rajab M, Estes NAM III, Link MS. Precordial thump for cardiac arrest is effective for asystole but not for ventricular fibrillation. *Heart Rhythm* 2009;6:1495-500.

Copyright © 2010 Massachusetts Medical Society.